

## CASE REPORT

# Congenital High Airway Obstruction Syndrome: Antenatal Ultrasound Findings

<sup>1</sup>Hemant Thakur, <sup>2</sup>Shirish Vaidya

## ABSTRACT

**Objective:** The objective of this study was to describe the antenatal ultrasound appearances of congenital high airway obstruction syndrome (CHAOS), which typically manifests as large echogenic lungs acquiring whole of the thorax and dilatation of the trachea distal to the obstruction and causing intrinsic laryngeal/tracheal obstruction.

**Case report:** A 30-year-old pregnant female with 24 weeks gestation come for routine absolute neutrophil count (ANC) scan. Ultrasonography (USG) was performed, and large echogenic lungs occupying whole of the thoracic cavity compressing the heart in between and causing inversion of the bilateral domes of the diaphragm were found. There was dilatation of the trachea distal to the lesion and polyhydramnios.

**Conclusion:** The described USG finding of CHAOS may be useful in deciding when to include this entity in the differential diagnosis of enlarged echogenic lungs.

**Keywords:** Congenital high airway obstruction syndrome, Laryngeal atresia, Polyhydramnios.

**How to cite this article:** Thakur H, Vaidya S. Congenital High Airway Obstruction Syndrome: Antenatal Ultrasound Findings. *Int J Recent Surg Med Sci* 2017;3(2):114-116.

**Source of support:** Nil

**Conflict of interest:** None

## INTRODUCTION

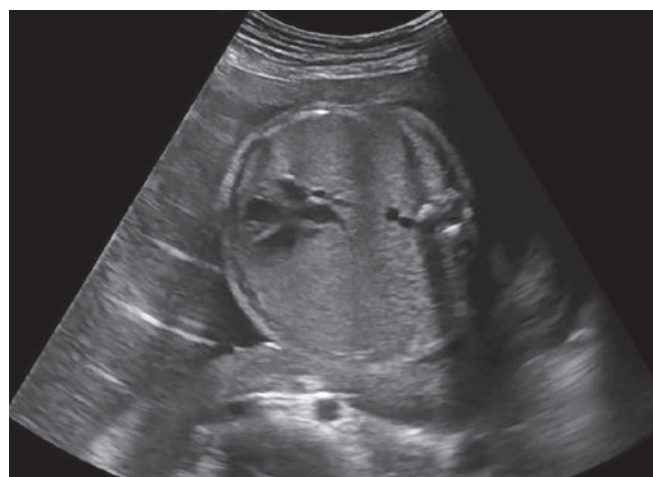Congenital high airway obstruction syndrome is defined as complete or partial obstruction of the fetal upper airways. This clinical condition was brought into notice first by Hedrick in the late 1900s.<sup>1</sup> The true incidence of CHAOS is unknown. It is usually incompatible with life and results in stillbirth or death shortly after delivery due to airway obstruction.<sup>2</sup> The CHAOS is usually caused by intrinsic atresia or stenosis of the larynx or trachea and obstructing laryngeal cysts and

obstructing tumors of the oropharynx and the cervical regions. Moreover, laryngeal atresia appears to be the most frequent cause.<sup>1,3</sup> Bilaterally enlarged hyperechoic lungs, dilated airways, and flattened or inverted diaphragm are the typical prenatal sonographic findings. The other findings that can be associated with this are fetal anasarca, polyhydramnios, and nonimmune hydrops.<sup>4</sup> Prenatal definition of fetal airway obstruction has come into prominence with the hope of neonatal outcome improvements due to the recently described management options.<sup>5</sup>

## CASE REPORT

A 30-year-old pregnant female with 24 weeks gestation come for routine ANC scan. On USG, there was enlarged echogenic lungs (Fig. 1) occupying whole of the thoracic cavity compressing the heart in between (Fig. 2) and causing inversion of the bilateral domes of the diaphragm (Fig. 3). There was dilatation of the trachea distal to the atresia (Fig. 4) and polyhydramnios (Fig. 5). There was also presence of club feet (Fig. 6) and absence of unilateral kidney (right) (Fig. 7). She was para 2 with normal first child.

We explained the family of the patient about the possible unfavorable outcome and asked the patient for the autopsy of the fetus but family refused.

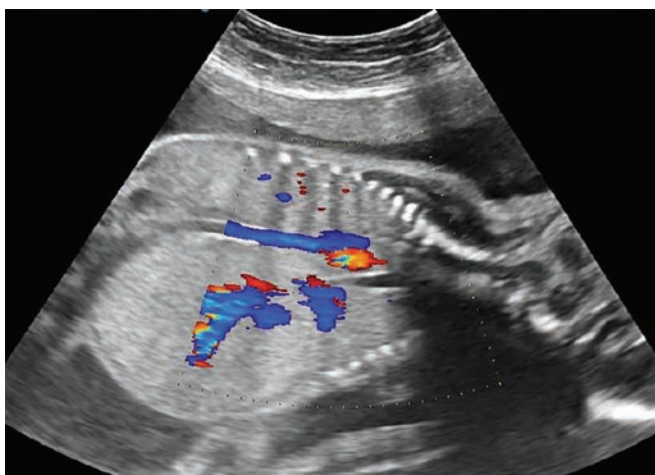


**Fig. 1:** Transverse ultrasound image with large echogenic lungs occupying whole of the thoracic cavity and causing compression of the heart

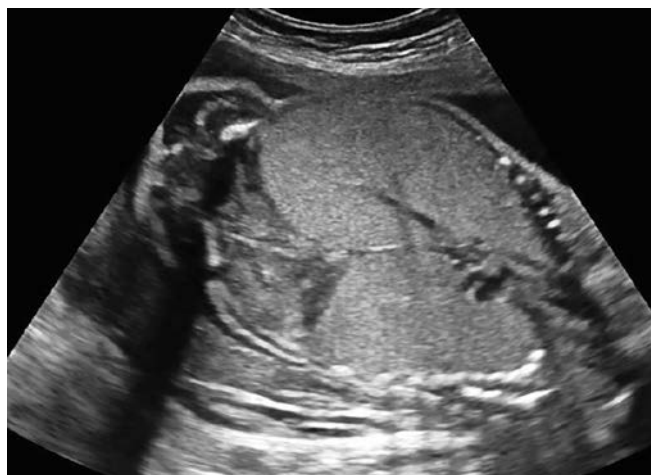<sup>1</sup>Junior Resident, <sup>2</sup>Associate Professor

<sup>1,2</sup>Department of Radiodiagnosis, Jawaharlal Nehru Medical College, Wardha, Maharashtra, India

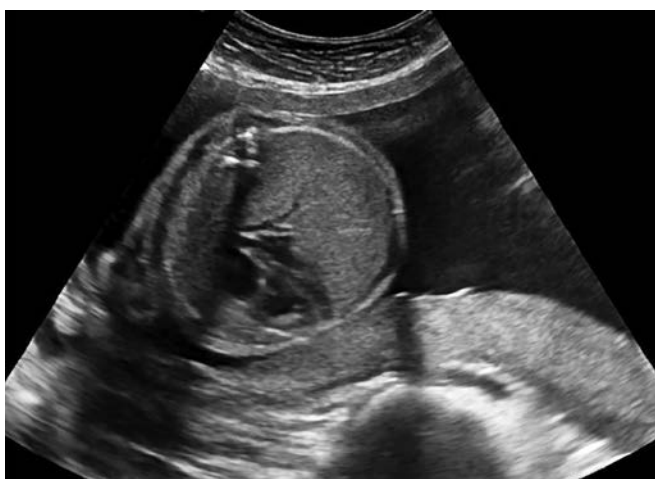**Corresponding Author:** Hemant Thakur, Junior Resident Department of Radiodiagnosis, Jawaharlal Nehru Medical College, Wardha, Maharashtra, India, Phone: +917152287701 e-mail: hmt168102@gmail.com



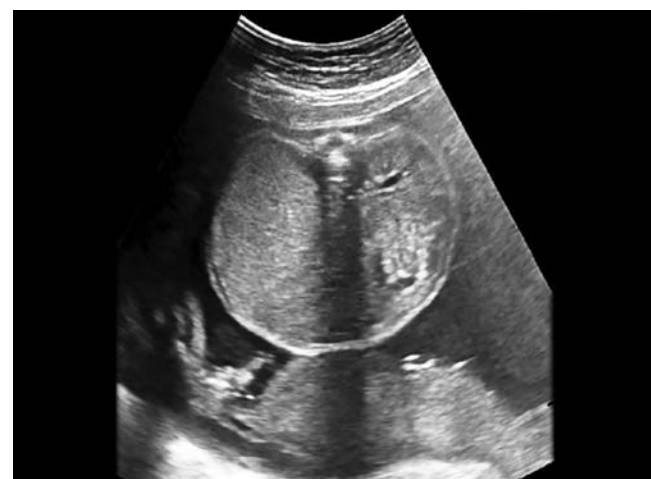**Fig. 2:** Coronal ultrasound image with echogenic lungs and dilatation of the trachea distal to the obstruction



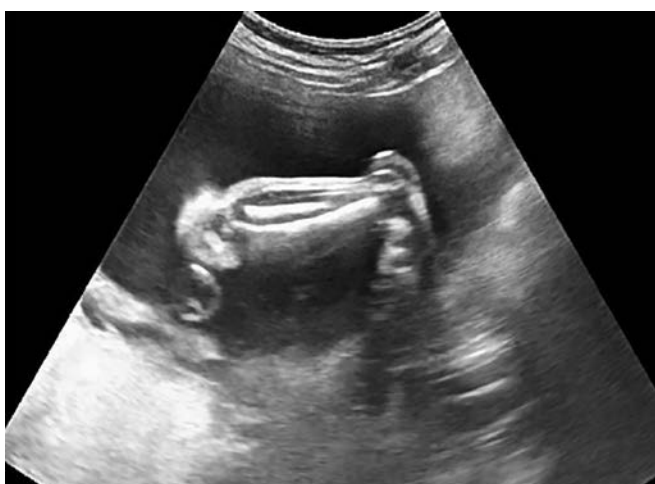**Fig. 3:** Coronal ultrasound scan with bilateral enlarged echogenic lungs causing inversion of the diaphragm



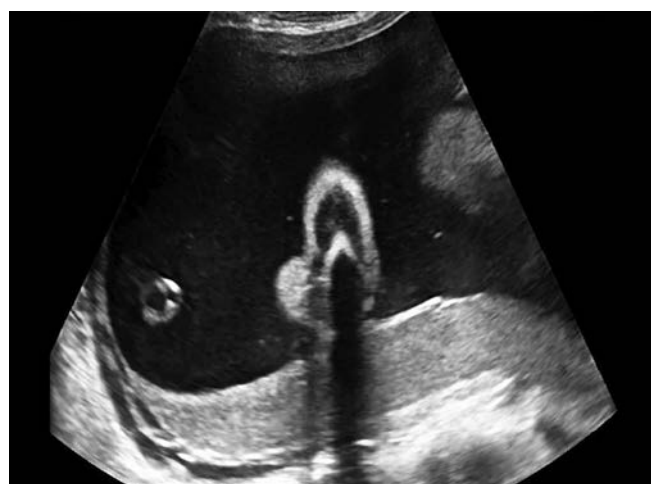**Fig. 4:** Transverse ultrasound scan revealing central axis of the heart compressed between the enlarged echogenic lungs



**Fig. 5:** Transverse ultrasound image with absence of right kidney



**Fig. 6:** Ultrasound image revealing club foot



**Fig. 7:** Ultrasound scan revealing single large amniotic fluid pocket: Polyhydramnios

## DISCUSSION

Smith and Bain<sup>6</sup> have classified laryngeal atresia into three types: Type I, in which there is complete atresia of the larynx with midline fusion of the arytenoid cartilages

and intrinsic muscles; type II, in which there is infra-glottic obstruction which is usually characterized by a dome-shaped cricoid cartilage obstructing the lumen; and type III, in which there is occlusion of the anterior fibrous

membrane and fusion of the arytenoid cartilages at the level of the vocal processes. Laryngeal atresia is a rare congenital malformation and is usually fatal. The malformation is caused by nondevelopment of the 6th branchial arch during normal embryological development.

Laryngeal atresia can be associated with various syndromes like partial trisomy 9 and 16, resulting in maternal translocation, which has also been reported in the literature.<sup>7,8</sup>

Antenatal USG shows dilated tracheobronchial tree, an enlarged hyperechoic lungs, ascites, and an inverted or flattened dome of the diaphragm. In high airway obstruction, the nonclearance of fluid from the lungs results in parenchymal hyperplasia, which is apparent on USG as enlarged hyperechoic lungs; this condition was recognized by Dolkart et al,<sup>9</sup> Morrison et al,<sup>10</sup> and Liggins.<sup>11</sup> In laryngeal atresia, the trachea is dilated because of nonclearance of fluid (which is normally secreted by the lungs). An enlarged lung causes compression of the great veins and the right atrium, and this leads to ascites.<sup>10,12</sup> Compression of the esophagus due to a dilated trachea results in polyhydramnios.<sup>13</sup> The identification of airway obstruction is important to establish the diagnosis of CHAOS and to distinguish it from other causes of echogenic lungs, such as bilateral congenital cystic adenomatoid malformation or sequestrations. It is also necessary to distinguish CHAOS from extrinsic causes of airway obstruction. The level of airway obstruction needs to be established with accuracy if any intervention is planned as it can help to choose between fetal and neonatal interventions.<sup>14</sup>

Magnetic resonance imaging (MRI) also shows a dilated airway up to the level of the obstruction and is better at identifying the level of obstruction due to higher intrinsic soft tissue contrast. The MRI findings include increased lung volumes with abnormally increased signal. There may be flattening or inversion of the diaphragm, small anteriorly displaced heart with centrally positioned axis, ascites, and other features of nonimmune hydrops, polyhydramnios, limb anomalies, etc.<sup>14</sup>

This malformation is generally fatal; however, there are reports of a few cases that have been successfully treated with neonatal interventions, such as *ex utero* intrapartum treatment.<sup>15,16</sup>

## CONCLUSION

Congenital high airway obstruction syndrome is a rare cause of congenital airway obstruction, which is incompatible with life. Antenatal imaging with ultrasound usually shows typical findings, which can lead to diagnosis and can be helpful in early termination of the pregnancy. The ANC USG is used for the diagnosis, but

MRI is considered superior to ultrasound in identifying the level of obstruction.

## REFERENCES

- Roybal JL, Liechty KW, Hedrick HL, Bebbington MW, Johnson MP, Coleman BG, Adzick NS, Flake AW. Predicting the severity of congenital high airway obstruction syndrome. *J Pediatr Surg* 2010 Aug;45(8):1633-1639.
- Joshi P, Satija L, George RA, Chatterjee S, D'Souza J, Raheem A. Congenital high airway obstruction syndrome-antenatal diagnosis of a rare case of airway obstruction using multimodality imaging. *MJAFI* 2012 Jan;68(1):78-80.
- Sanford E, Saadai P, Lee H, Slavotinek A. Congenital high airway obstruction sequence (CHAOS): a new case and a review of phenotypic features. *Am J Med Genet A* 2012 Dec;158A(12):3126-3136.
- Garg MK. Case report: antenatal diagnosis of congenital high airway obstruction syndrome. Laryngeal atresia. *Indian J Radiol Imaging* 2008 Nov;18(4):350-351.
- Courtier J, Poder L, Wang ZJ, Westphalen AC, Yeh BM, Coakley FV. Fetal tracheolaryngeal airway obstruction: prenatal evaluation by sonography and MRI. *Pediatr Radiol* 2010 Nov;40(11):1800-1805.
- Smith II, Bain AD. Congenital atresia of the larynx: a report of nine cases. *Ann Otol Rhinol Laryngol* 1965 Jun;74:338-349.
- Baker DC Jr, Savetsky L. Congenital partial atresia of the larynx. *Laryngoscope* 1966 Apr;76(4):616-620.
- Van den Boogaard MJ, De Pater J, Hennekam RC. A case with laryngeal atresia and partial trisomy 9 due to maternal 9;16 translocation. *Genet Couns* 1991 Feb;2(2):83-91.
- Dolkart LA, Reimers FT, Wertheimer IS, Wilson BO. Prenatal diagnosis of laryngeal atresia. *J Ultrasound Med* 1992 Sep;11(9):496-498.
- Morrison PJ, Macphail S, Williams D, McCusker G, McKeever P, Wright C, Nevin NC. Laryngeal atresia or stenosis presenting as second-trimester fetal ascites: diagnosis and pathology in three independent cases. *Prenat Diagn* 1998 Sep;18(9):963-967.
- Liggins GC. Growth of the fetal lung. *J Dev Physiol* 1984 Jun;6:237-248.
- Minior VK, Gagner JP, Landi K, Stephenson C, Greco MA, Monteagudo A. Congenital laryngeal atresia associated with partial diaphragmatic obliteration. *J Ultrasound Med* 2004 Feb;23(2):291-296.
- Onderoglu L, Saygan Karamürsel B, Bulun A, Kale G, Tunçbilek E. Prenatal diagnosis of laryngeal atresia. *Prenat Diagn* 2003 Apr;23(4):277-280.
- Guimaraes CV, Linam LE, Kline-Fath BM, Donnelly LF, Calvo-Garcia MA, Rubio EI, Livingston JC, Hopkin RJ, Peach E, Lim FY, et al. Prenatal MRI findings of fetuses with congenital high airway obstruction sequence. *Korean J Radiol* 2009 Mar-Apr;10(2):129-134.
- Crombleholme TM, Sylvester K, Flake AW, Adzick NS. Salvage of a fetus with congenital high airway obstruction syndrome by *ex utero* intrapartum treatment (EXIT) procedure. *Fetal Diagn Ther* 2000 Sep-Oct;15(5):280-282.
- Kanamori Y, Kitano Y, Hashizume K, Sugiyama M, Tomonaga T, Takayasu H, Egami S, Goishi K, Shibuya K, Kawana Y, et al. A case of laryngeal atresia (congenital high airway obstruction syndrome) with chromosome 5p deletion syndrome rescued by *ex utero* intrapartum treatment. *J Pediatr Surg* 2004 Jan;39(1):E25-E28.