

Giant Retroperitoneal Sarcoma: A Case Report and Review of Literature

Melissa K. Saad¹ Elias Fiani² Ali Abdullah³ Elias Saikaly⁴

¹Department of General Surgery, Saint George Hospital University Medical Center, University of Balamand, El-Koura, Lebanon

²Department of Gastroenterology, Saint George Hospital University Medical Center, Beirut, Lebanon

³Department of Radiology, Saint George Hospital University Medical Center, University of Balamand, El-Koura, Lebanon

⁴Department of General Surgery, Colorectal Surgery, Saint George Hospital University Medical Center, University of Balamand, El-Koura, Lebanon

Address for correspondence Elias Saikaly, MD, Department of General Surgery, Colorectal Surgery, Saint George Hospital University Medical Center, University of Balamand, El-Koura, Lebanon (e-mail: dreliassaikaly@gmail.com).

Int J Recent Surg Med Sci 2020;6:41–44

Abstract

Keywords

- ▶ sarcoma
- ▶ sarcoma retroperitoneal
- ▶ sarcoma retroperitoneal

Liposarcomas are neoplasms of mesodermal origin derived from adipose tissue representing 10 to 14% of all soft tissue sarcomas, with the most frequent subtype being liposarcoma. Given that the retroperitoneum is a large space in which the retroperitoneal liposarcoma can grow asymptotically up until a mass effect develop. Hence, patients usually present late with symptoms with possible invasion to nearby structures. These tumors are known to reach significantly large dimension, despite their poor vascularization and can grow to enormous size, the average diameter of the tumor is 20 to 25 cm with a weight of 15 to 20 kg. Surgery with en-bloc resection of the tumor and adherent nearby structures, with intact capsule, remains the gold standard in surgical management of retroperitoneal sarcomas. Herein, we present a case of 52 year old male patient with a huge 48 cm right-sided retroperitoneal liposarcoma, managed surgically by en bloc excision of the tumor, right kidney, right ureter, right adrenal gland, and the right colon.

Introduction

Liposarcomas are neoplasms of mesodermal origin derived from adipose tissue representing 10 to 14% of all soft tissue sarcomas, with the most frequent subtype being liposarcoma (41%).¹ Retroperitoneal liposarcomas comprise 0.07 to 0.2% of all neoplasia.² Approximately 85% of these are malignant, liposarcoma is the most frequent histopathological variant of the retroperitoneal sarcomas.³ In view that the retroperitoneum is a large space in which the retroperitoneal liposarcoma can grow asymptotically up until a mass effect develop. Hence, patients usually present late with symptoms like vague abdominal discomfort, increasing abdominal girth and lump abdomen. Diagnosis is usually made on the basis of computed tomography (CT) scans of the abdomen and pelvis. Surgery with en bloc resection of the tumor and adherent nearby structures is the gold standard of treatment. Herein, we present a case of 52-year-old male patient with a huge 48-cm right-sided retroperitoneal liposarcoma, managed surgically by en bloc excision of the tumor, right kidney, right ureter, right adrenal gland, and the right colon.

Case Presentation

A 52-year-old male patient, previously healthy with no previous abdominal surgeries or any remarkable family history, presenting with the complaint of increased abdominal girth, 6 months prior to presentation. Patient denied any weight loss, fatigue, and change bowel habits. On physical exam, his abdomen was markedly swollen and felt hard without any tenderness. Blood workup including a complete blood count, electrolytes, creatinine, and liver function tests done and turned out to be normal. Hence, a colonoscopy and CT scan abdomen pelvis with intravenous (IV) contrast were scheduled. Colonoscopy was normal. However the CT scan showed solid mass located in the right abdomen, with its central region not absorbing the intravenous contrast, which was attributed to central necrosis or cystic degeneration. The mass occupied the right portion of the abdomen displacing the right colon, with its upper borders to the lower edge and of the liver and lower borders reaching the pelvis (▶ Figs. 1 and 2) and in close proximity to the rectosigmoid colon and compressing the bladder. The size of this mass was

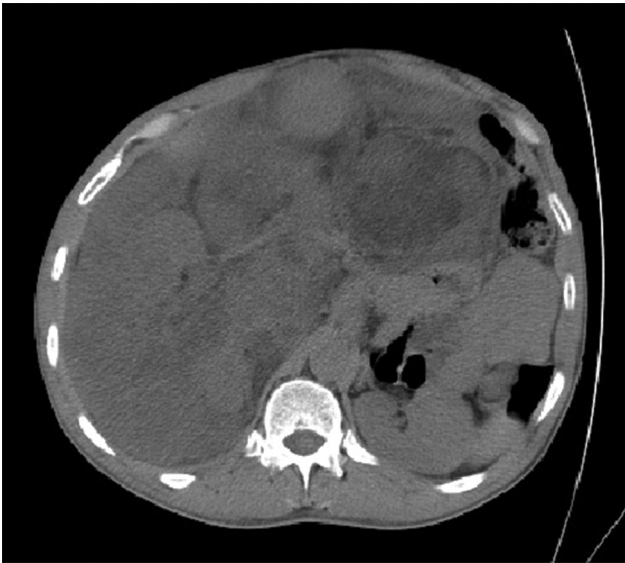

Fig. 1 CT scan showing the large retroperitoneal sarcoma with abdominal structures being displaced to the left. CT, computed tomography.

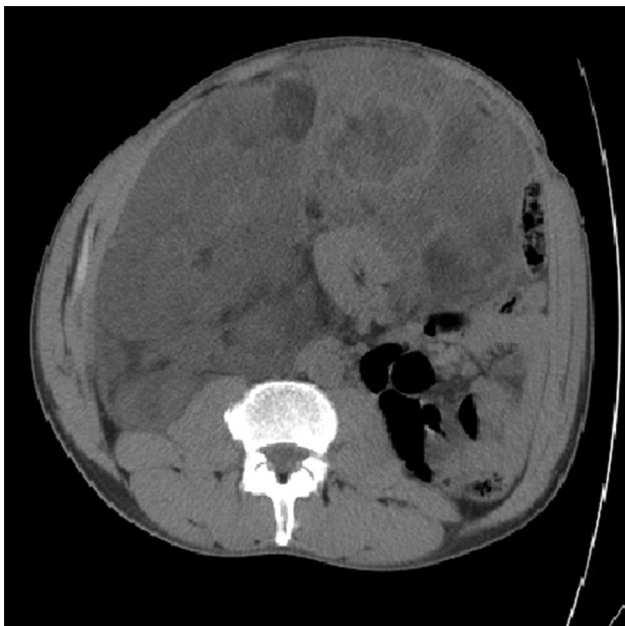

Fig. 2 CT scan showing the large retroperitoneal sarcoma. CT, computed tomography.

measured to be 48 cm × 31 cm × 12 cm. The position of the mass was displacing the anatomical structures and organs away from their natural position. In addition, the tumor was in contact with the right kidney, the inferior vena cava and the right renal vein causing mild dilation of the right pelvis of the kidney. Patient was scheduled for surgical excision of the mass with an R0 resection as the aim. Surgery performed with a generous midline incision from the xiphoid process to the pubic bone with extension to the right subcostal area (► **Fig. 3**). The tumor was exposed, displacing the right colon past the midline, with no clear cleavage plane in between. We opted for en bloc resection of the tumor, right adrenal, right

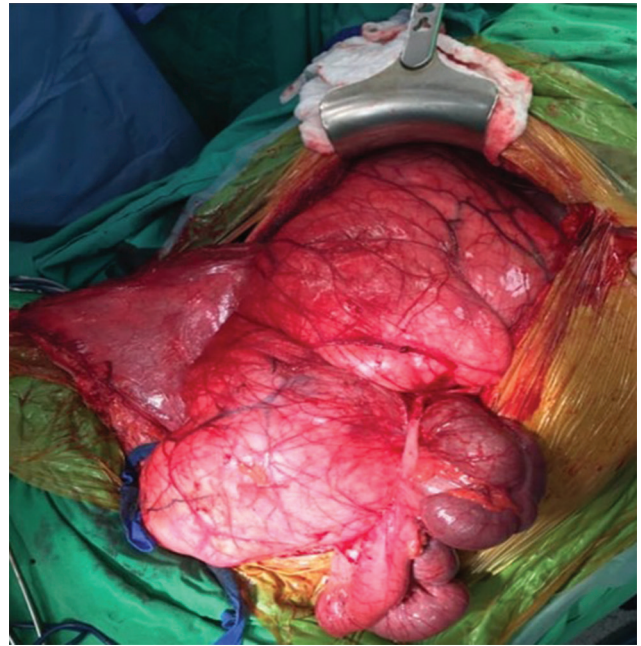


Fig. 3 Intraoperative picture showing the exposed tumor after the midline incision being extended to the right subcostal.

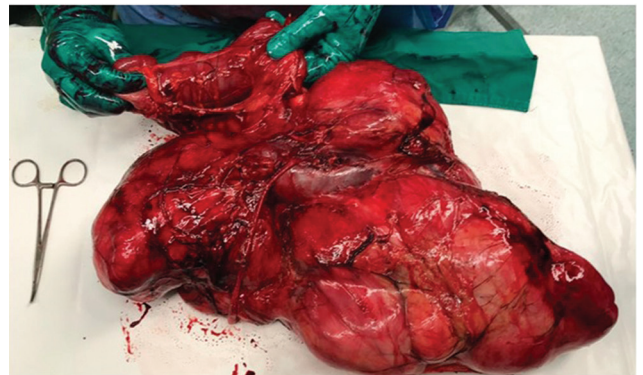


Fig. 4 Tumor with kidney, ureter and the right colon en bloc excision.

kidney, and the right colon (► **Fig. 4**). Pathology turned out to be well differentiated liposarcoma. Patient had a smooth postoperative course and was discharged home day 4 after surgery. On 2-year follow up, the patient is disease free as documented by imaging with no complaint.

Discussion

In view that retroperitoneal liposarcomas can grow asymptotically up until a mass effect starts to appear. These tumors are known to reach significantly large dimension, despite their poor vascularization, and can grow to enormous size, the average diameter of the tumor is 20 to 25 cm with a weight of 15 to 20 kg.² Surgery with en bloc resection of the tumor and adherent nearby structures, with intact capsule, remains the gold standard in surgical management of retroperitoneal sarcomas. Moreover, only a complete surgery has been proven to improve the overall survival in patients diagnosed with retroperitoneal sarcomas, with the most

important variable being en bloc resection of the tumor with adherent nearby structures. Aforementioned, studies have shown that the median survival of patients with complete resection was 103 months versus 18 months with incomplete resection, similar to when no surgery was done at all.¹ For tumors more than 10 cm in dimensions, complete R0 resection can be achieved in 70% of cases; however, multiorgan resection is deemed necessary in 50% of cases to achieve R0 resection.³ Hence, the resection of a retroperitoneal sarcoma of remarkable size is a challenge due to multiple factors, the anatomical site, absence of an anatomically evident vascular, and lymphatic pedicles making it hard to obtain safe margin, adhesions to nearby organs, and the great vessels. In our case, the tumor was among the largest reported in literature (►Table 1) adherent to the right kidney and right colon, hence curative surgery necessitates the en bloc excision of the right retroperitoneal tumor, right adrenal gland, right kidney, right ureter, and the right colon. Giant retroperitoneal sarcomas has been rarely reported in the medical literature. To our knowledge, 20 cases has been reported with tumor size 40 cm in greater dimension and above (►Table 1), with

a mean age of presentation being 53 years old, the female-to-male ratio is 8:12, 50% requiring multiorgan resection and the rate of R0 resection was 100%. Following surgical resection, 50 to 100% of liposarcomas recur from residual tissue, which is the primary cause of death.⁴ Therefore an aggressive surgical behavior is mandated, with the resection of the structures and viscera adjacent to the pathological process in an attempt to obtain an R0 resection. The use of chemotherapy is limited to metastatic disease as palliation, along with radiotherapy in nonoperable cases or incomplete resection.^{5,6} In summary, the ability to achieve R0 resection along with the histopathologic grade will solely determine the disease prognosis. The abovementioned two factors are determined during surgery and are very hard to elucidate preoperatively.

Conclusion

Retroperitoneal liposarcomas are a unique disease and require an aggressive surgical approach with multiorgan resection if necessary, in accordance with the ability of the patient to tolerate the procedure. Surgery with R0 resection

Table 1 Giant retroperitoneal sarcomas reported in literature

No.	Author (y)	Gender/age (y)	Preimaging	Size (cm ³)	Histological subtype	Complete resection	Multiorgan resection
1	Herrera-Gómez et al ⁷ (2008)	M/24	CT	80 × 50 × 35	Undifferentiated	Yes (R0)	No
2	Zeng et al ⁸ (2017)	M/45	CT	65 × 45 × 30	Well-differentiated	Yes (R0)	No
3	Benseler et al ⁹ (2009)	M/39	CT	60 × 50 × 36	Well-differentiated	Yes (R0)	Yes
4	Hazen and Cocieru ¹⁰ (2017)	M/64	CT	60 × 42 × 31	Poorly differentiated	Yes (R0)	No
5	Akhoondinasab et al ¹¹ (2011)	M/54	US/CT	58 × 45 × 36	Well-differentiated	Yes (R0)	No
6	De Nardi et al ¹² (2012)	M/40	CT	50 × 49 × 35	Well-differentiated	Yes (R0)	No
7	Yol et al ¹³ (1998)	M/63	US/CT	50 × 45 × 32	Myxoid	Yes (R0)	Yes
8	Selmani et al ¹⁴ (2011)	F/58	US/CT	50 × 35 × 25	Well-differentiated	Yes (R0)	No
9	Our Case	M/52	CT	48 × 31 × 12	Well-differentiated	Yes (R0)	Yes
10	Clar et al ¹⁵ (2009)	M/66	CT	47 × 42 × 25	Well-differentiated	Yes (R0)	Yes
11	Sharma et al ¹⁶ (2013)	F/60	CT	47 × 40 × 25	Well-differentiated	Yes (R0)	No
12	Morandeira et al ¹⁷ (2008)	F/63	CT	45 × 43 × 24	Myxoid	Yes (R0)	Yes
13	Hashimoto et al ¹⁸ (2010)	M/41	CT	45 × 40 × 30	Poorly differentiated	Yes (R0)	Yes
14	Oh et al ¹⁹ (2016)	F/71	US/CT	45 × 30 × 11	Well-differentiated	Yes (R0)	No
15	Xie et al ²⁰ (2006)	F/41	US/CT	43 × 40 × 25	Well-differentiated	Yes (R0)	No
16	Caizzone et al ²¹ (2015)	F/64	CT	42 × 37 × 18	Mixed	Yes (R0)	Yes
17	Bansal et al ²² (2013)	M/52	CT	40 × 35 × 35	Mixed	Yes (R0)	Yes
18	Liu et al ²³ (2013)	F/55	CT	40 × 30 × 20	Well-differentiated	Yes (R0)	No
19	Zheng et al ²⁴ (2011)	M/55	CT	40 × 30 × 20	NA	Yes (R0)	Yes
20	Salemis et al ²⁵ (2009)	F/54	CT/MRI	40 × 26 × 16	Mixed	Yes (R0)	Yes
21	Fu Qiang ²⁶ (2007)	M/52	CT	40 × 30 × 10	Well-differentiated	Yes (R0)	Yes

Abbreviations: CT, computed tomography; F, female; M, male, MRI, magnetic resonance imaging; US, ultrasound.

remains the cornerstone in its management, with chemotherapy and radiotherapy reserved for palliation.

Conflict of Interest

None declared.

References

- Lewis JJ, Leung D, Woodruff JM, Brennan MF. Retroperitoneal soft-tissue sarcoma: analysis of 500 patients treated and followed at a single institution. *Ann Surg* 1998;228(3):355–365
- Echenique-Elizondo M, Amondarain-Arratibel JA. [Giant retroperitoneal liposarcoma] (in Spanish) *Cir Esp* 2005;77(5):293–295
- Hassan I, Park SZ, Donohue JH, et al. Operative management of primary retroperitoneal sarcomas: a reappraisal of an institutional experience. *Ann Surg* 2004;239(2):244–250
- Leão P, Vilaça S, Oliveira M, Falcão J. Giant recurrent retroperitoneal liposarcoma initially presenting as inguinal hernia: Review of literature. *Int J Surg Case Rep* 2012;3(3):103–106
- Azpiazu Arnaiz P, Muro Bidaurre I, De Frutos Gamero A, et al. Retroperitoneal tumors. Retroperitoneal myxoid liposarcoma. Report of a new case.] (in Spanish) *Arch Esp Urol* 2000;53(2):170–173
- Romero Pérez P, Rafie Mazketli W, Amat Cecilia M, Merenciano Cortina FJ, Gonzalez Devesa M. [Adipose retroperitoneal tumors. Apropos a giant myxoid liposarcoma.] (in Spanish) *Actas Urol Esp* 1996;20(1):79–84
- Herrera-Gómez A, Ortega-Gutiérrez C, Betancourt AM, Luna-Ortiz K. Giant retroperitoneal liposarcoma. *World J Surg Oncol* 2008;6:115–115
- Zeng X, Liu W, Wu X, et al. Clinicopathological characteristics and experience in the treatment of giant retroperitoneal liposarcoma: a case report and review of the literature. *Cancer Biol Ther* 2017;18(9):660–665
- Benseler V, Obed A, Schubert T, Schlitt HJ, Bolder U. [Case report–surgical therapy of a retroperitoneal liposarcoma weighing 45 Kg.] (in German) *Zentralbl Chir* 2009;134(2):174–177
- Hazen B, Cocieru A. Giant retroperitoneal sarcoma. *J Gastrointest Surg* 2017;21(3):602–603
- Akhoondinasab MR, Omranifard M. Huge retroperitoneal liposarcoma. *J Res Med Sci* 2011;16(4):565–567
- De Nardi P, Bissolati M, Cristallo M, Staudacher C. Recurrent giant liposarcoma of the spermatic cord. *Urology* 2012;79(1):113–114
- Yol S, Tavli S, Tavli L, Belviranlı M, Yosunkaya A. Retroperitoneal and scrotal giant liposarcoma: report of a case. *Surg Today* 1998;28(3):339–342
- Selmani R, Begovic G, Janevski V, Rushiti Q, Karpuzi A. Giant retroperitoneal liposarcoma: a case report. *Prilozi / Makedonska akademija na naukite i umetnostite, Oddelenie za biološki i medicinski nauki = Contributions/Macedonian Academy of Sciences and Arts. Section Biol Med Sci*, 2011;32:323–332
- Clar H, Leithner A, Gruber G, Werkgartner G, Beham A, Windhager R. Interdisciplinary resection of a giant retroperitoneal liposarcoma of 25 kg. *ANZ J Surg* 2009;79(12):957
- Sharma M, Mannan R, Bhasin TS, Manjari M, Punj R. Giant inflammatory variant of well differentiated liposarcoma: a case report of a rare entity. *J Clin Diagn Res* 2013;7(8):1720–1721
- Morandiera A, Prieto J, Poves I, Sánchez Cano JJ, Díaz C, Baeta E. Giant retroperitoneal sarcoma. *Can J Surg* 2008;51(4):E79–E80
- Hashimoto Y, Hatakeyama S, Tachiwada T, et al. Surgical treatment of a giant liposarcoma in a Japanese man. *Adv Urol* 2010;2010:943073
- Oh SD, Oh SJ, Suh BJ, et al. A giant retroperitoneal liposarcoma encasing the entire left kidney and adherent to adjacent structures: a case report. *Case Rep Oncol* 2016;9(2):368–372
- Xie M, Zeng QL, Wen KM. Giant retroperitoneal liposarcoma: experiences in diagnosis and treatment of two cases. *Guizhou Med J* 2006;30:30–31
- Caizzone A, Saladino E, Fleres F, et al. Giant retroperitoneal liposarcoma: Case report and review of the literature. *Int J Surg Case Rep* 2015;9:23–26
- Bansal VK, Misra MC, Sharma A, Chhabra A, Murmu LR. Giant retroperitoneal liposarcoma- renal salvage by autotransplantation. *Indian J Surg* 2013;75(2):159–161
- Liu B, Wang QF, Yu JH, Wang DG, Zhang Y, Xu YC. Giant abdominal liposarcoma: a case report. *Zhongguo Laonianxue Zazhi* 2013;33:452
- Zheng SW, Wang SL, An WK. Giant retroperitoneal liposarcoma: a case report. *Clin J Med Off* 2011;39:333
- Salemis NS, Tsiambas E, Karameris A, Tsohataridis E. Giant retroperitoneal liposarcoma with mixed histological pattern: a rare presentation and literature review. *J Gastrointest Cancer* 2009;40(3,4):138–141
- Fu Q. Huge retroperitoneal liposarcoma: a case report. *Chin Med J (Engl)* 2007;120(12):1117–1118